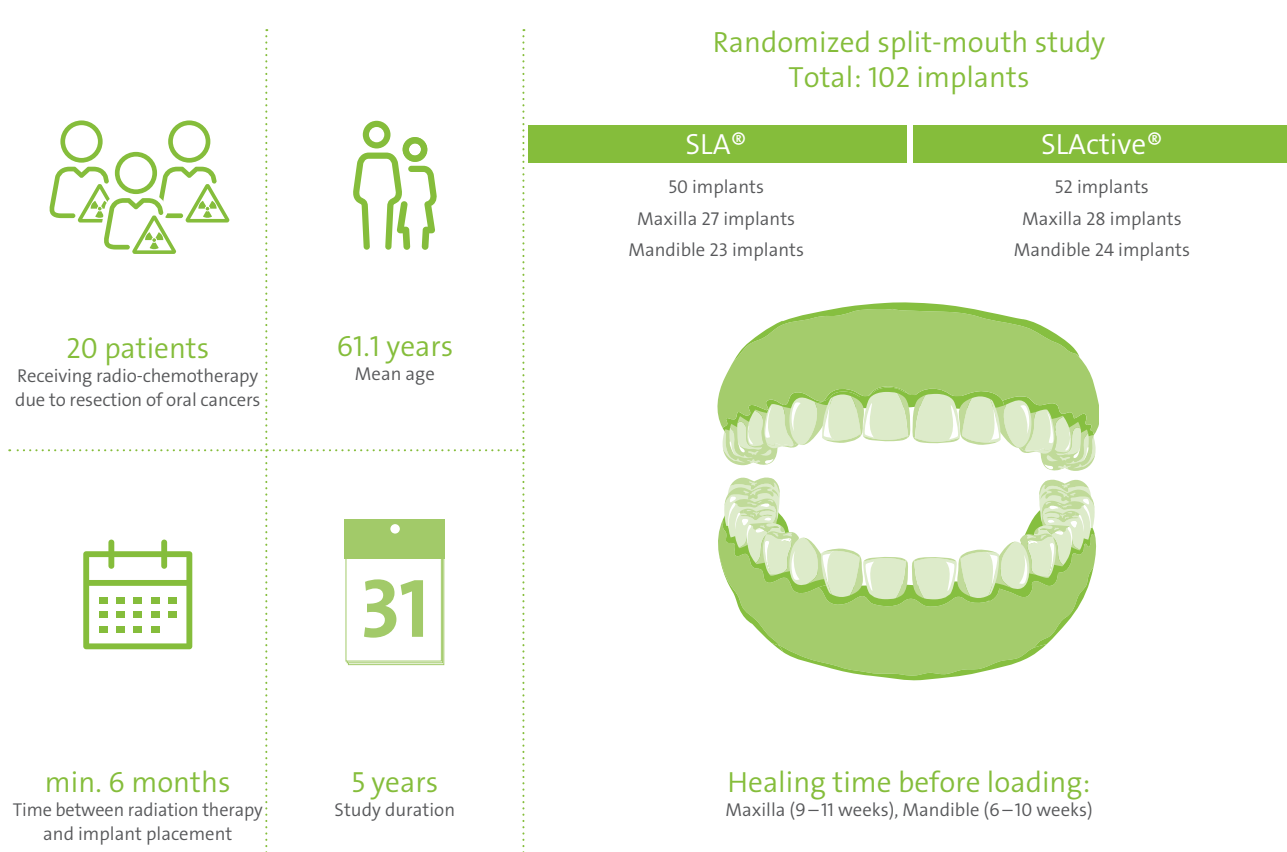


Rehabilitation of irradiated patients with Straumann® SLA® and SLActive® Implants: five-year follow-up

Study design¹



Aim

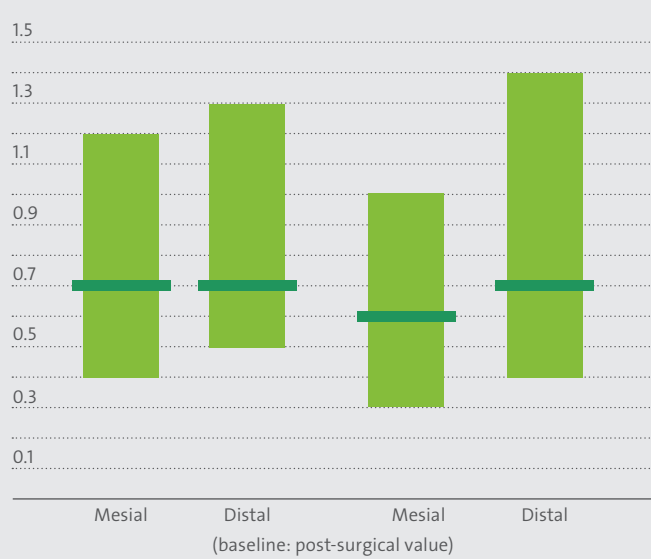
12 months

To evaluate the clinical and radiological parameters of SLA®/SLActive® surface implants in irradiated patients after the initial 12-month loading period up to 5 years.

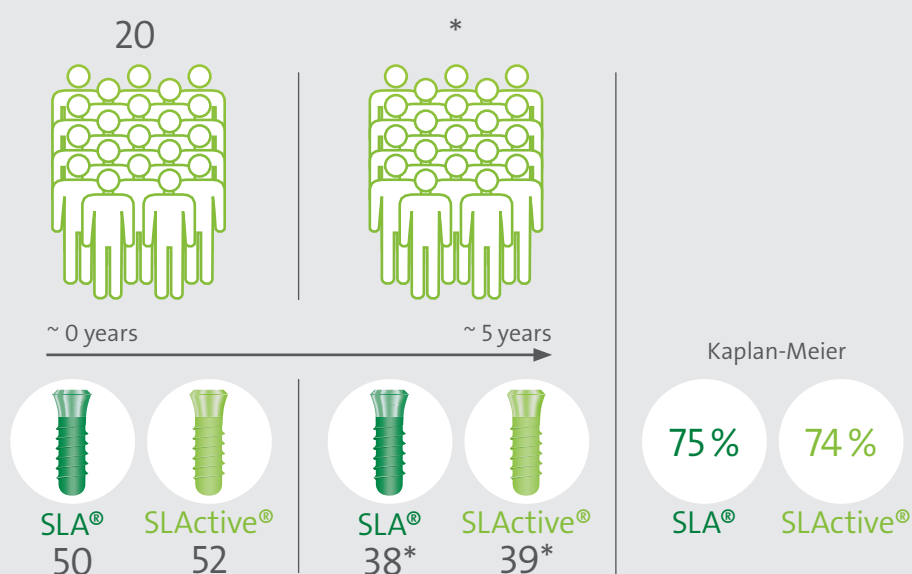
5 years

Results^{2,3}

Mean crestal bone level change



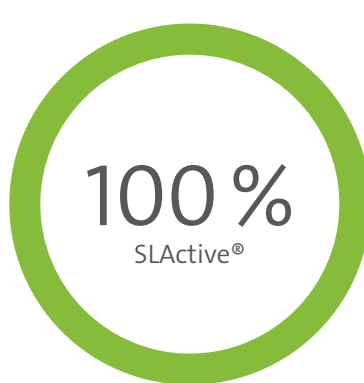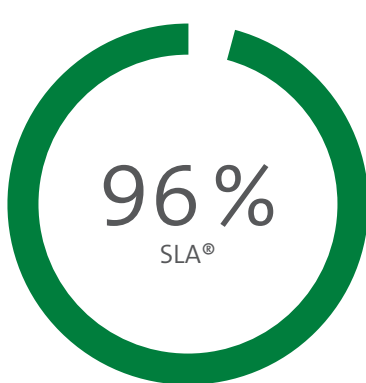
The crestal bone level was stable within 5 years after placement and similar to data in non-irradiated patients²



* 1 patient had tumour recurrence >>> resection to remove bone and 5 implants; 2 patients lost 1 implant before loading. Prosthetic rehabilitation could still take place successfully in these patients despite the loss of these implants; 4 patients died due to the cancer (-18) implants.

Clinical considerations^{2,3}

- SLActive® Implants can be used in irradiated patients with a high predictability of success.
- At the time of the patients' deaths, all the remaining implants were still in place in these patients and considered successful according the Buser success criteria⁴.
- Taking into account that the clinical performance and longevity of their implants would not be any different to the other implants in the study, had the patients survived, the **implant survival rate** would be: 96 % for SLA® | 100 % SLActive®.
- The crestal bone level was stable within 5 years after placement.
- Lower implant survival rates in patients with oral cancer may be associated with a higher mortality rate rather than a lack of osseointegration.



Implant survival rate (5 years)

1. Heberer S, Kilic S, Hossamo J, Raguse JD, Nelson K. Rehabilitation of irradiated patients with chemically modified and conventional sandblasted acid-etched implants: preliminary results of a split-mouth study. Clin Oral Implants Res. 2011 May;22(5):546-51. doi: 10.1111/j.1600-0501.2010.02050.x.
2. Nack C, Raguse JD, Stricker A, Nelson K, Nahles S. Rehabilitation of irradiated patients with chemically modified and conventional SLA® implants: five-year follow-up. J Oral Rehabil. 2015 Jan;42(1):57-64. doi: 10.1111/joor.12231.
3. Nelson K. Rehabilitation of irradiated patients with chemically modified and conventional SLA® implants: a clinical clarification. Letter to the editor. J Oral Rehabil. 2016 Submitted.
4. Buser D, Weber HP, Braegger U. The treatment of partially edentulous patients with ITI hollow-screw implants; presurgical evaluation and surgical procedures. Int J Oral Maxillofac Implants. 1990;5:165-174.